

Malignant extragonadal yolk sac tumor of the cervix in a 2-year-old female: case report

Aeia R Agarano,¹ Andrew U Alvarez,¹ Chastitee M Amora,¹ Alvin P Arreola,¹ Catherine E Autida,¹ Tessa Marie R Balboa,¹ Glennilyn L Bantilan,¹ Rocelyn M Barrientos,² Benjamin Alejandro R Untalan,¹ Cheryl Lyn A Diez,³ Maria Theresa Sanchez,⁴ Mae Concepcion Dolendo³

¹Southern Philippines Medical Center, JP Laurel Ave, Davao City, Philippines

²Central Philippine University, Jaro, Iloilo City, Philippines

³Children's Cancer and Blood Diseases Unit, Department of Pediatrics, Southern Philippines Medical Center, Bajada, Davao City, Philippines

⁴Department of Radiological and Imaging Sciences, Southern Philippines Medical Center, Bajada, Davao City, Philippines

Correspondence

Aeia Agarano
agaranoaeia@gmail.com

Received

31 May 2016

Accepted

22 July 2016

Published online

19 October 2016

Cite as

Agarano AR, Alvarez AU, Amora CM, Arreola AP, Autida CE, Balboa TMR, et al. Malignant extragonadal yolk sac tumor of the cervix in a 2-year-old female: case report. *SPMC J Health Care Serv.* 2016;2(1):6. <http://n2t.net/ark:/76951/jhcs27fmx8>

Copyright

© 2016 AR Agarano, et al.

ABSTRACT

Extragonadal germ cell tumors (EGGCT) are rare neoplasms. Yolk sac tumors (YST), a histologic variant of EGGCT, is rarely found in the cervix, especially among infants. We report a 2-year-old girl who presented with a 6-week history of foul smelling vaginal discharge and a cervical mass on computed tomography. Diagnosis of YST was established through biopsy, positive immunohistostaining with SALL4, placental alkaline phosphatase and alpha-fetoprotein (AFP), and an elevated serum AFP level. Because surgery can possibly affect the patient's reproductive capacity adversely, we initially decided to aim for remission with chemotherapy. The presence of a residual mass post-chemotherapy and an increasing trend in serum AFP levels prompted us to do radiotherapy for local control of the mass, with incomplete tumor response.

Keywords. cervico-uterine mass, germ cell tumor, radiotherapy, chemotherapy, immunohistostaining

INTRODUCTION

Malignant germ cell tumors (MGCT) are rare. Their incidence varies according to age and sex. They occur in the <20-year-old group with the incidence of 12 cases per million population.¹ Pediatric MGCT account for less than 3% of pediatric malignancies.² In children less than three years of age, MGCT are most commonly extragonadal or testicular in males and ovarian in females.¹ Extragonadal germ cell tumors (EGGCT) are germ cell neoplasms characterized by one of the histologies associated with gonadal origin, but are located outside of the gonads. Commonly, EGGCT are located in the mediastinum and retro-peritoneum. On rare occasions, EGGCT can be found in the pineal region, prostate, vagina, sacrococcygeal region, orbital region, liver and gastrointestinal tract.³ Cervical yolk sac tumor, a variant of EGGCT, is extremely rare, with only three cases in children less than three years old reported worldwide.⁴⁻⁶ We present a young girl who came in due to bloody vaginal discharge and was eventually diagnosed as having malignant extragonadal yolk sac tumor of the cervix.

CLINICAL FEATURES

A two-year-old girl from Southern Mindanao came to our institution for a six-week history of occasional bloody, brownish, foul-smelling vaginal discharge, with passage of meaty tissues and blood clots. This was associated

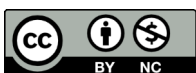with occasional vaginal pain. There was no reported fever, loss of appetite, weight loss, vomiting, dyspnea, abdominal pain, diarrhea or easy bruising. The patient's parents brought her to a local clinic, and she was initially prescribed with antibiotics, which did not stop the symptoms. During a second consult in a local hospital, a pelvic ultrasonography done on the patient revealed an echogenic solid structure, measuring 2.8 x 2.4 cm, in the pelvic region. She was then referred to a pediatric oncologist in our institution for further evaluation and management. The patient's past medical, family, birth, and maternal histories were all unremarkable. She had complete immunizations for a two-year-

IN ESSENCE

Yolk sac tumor of the cervix is rare among children less than three years old.

In this case report, a two-year-old girl was diagnosed to have a cervico-uterine yolk sac tumor. Because of the location and possible complications or consequences of surgery, remission by chemotherapy was attempted. The lack of a complete response prompted us to proceed with radiotherapy for local control. However, the persistence of a residual mass and rising tumor markers made us decide to pursue surgery.

Based on limited case reports, complete remission and local control of yolk sac tumors may require chemotherapy, radiotherapy and surgery.



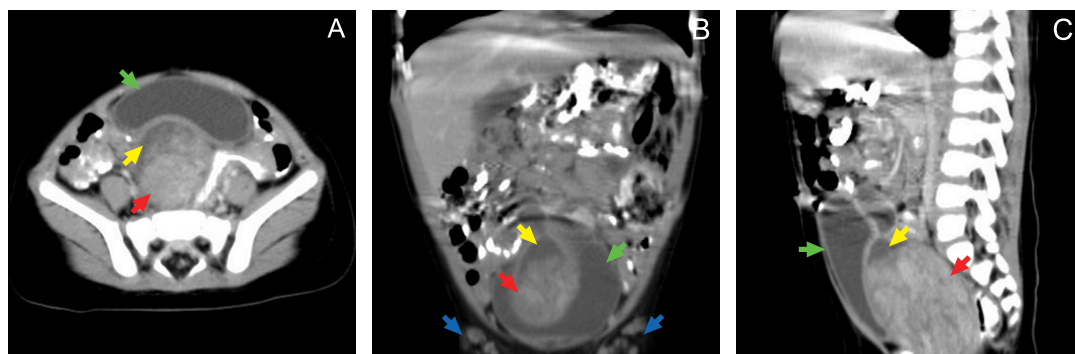


Figure 1 Abdominal computed tomography taken on admission, showing a large, fairly defined, heterogeneously enhancing soft tissue, measuring 6.4 x 5 x 4.3 cm, noted at the region of the cervix and uterus (A, B, and C: red arrows). Cystic components are seen contiguous to the enhancing mass (A, B, and C: yellow arrows). The sigmoid colon is compressed, demonstrating wall thickening. The mass causes compression and displacement of the urinary bladder anteriorly (A, B, and C: green arrows). Multiple enhancing lymph nodes are seen in the left and right inguinal areas (B: blue arrows).

old, and her growth and developmental milestones have been at par with age.

On physical examination during the initial admission, the patient was awake but was pale and weak looking. She had pale conjunctivae. The abdomen was globular. A firm, palpable hypogastric mass, measuring 7 x 3 cm, and bilateral inguinal lymph nodes were noted. The external genitalia showed no lesions. Vaginoscope also revealed an intact hymen. The rest of the physical and neurological

examination findings were unremarkable. Our primary consideration then was vaginal bleeding secondary to a urogynecological tumor.

DIAGNOSTIC APPROACHES

Blood workup revealed anemia of 94 g/L and leukocytosis of $10.60 \times 10^3/\mu\text{L}$, with 77% neutrophilic predominance. We requested for serum alpha-fetoprotein (AFP), lactate dehydrogenase (LDH) and beta human chorionic gonadotropin (beta-hCG), which all turned out

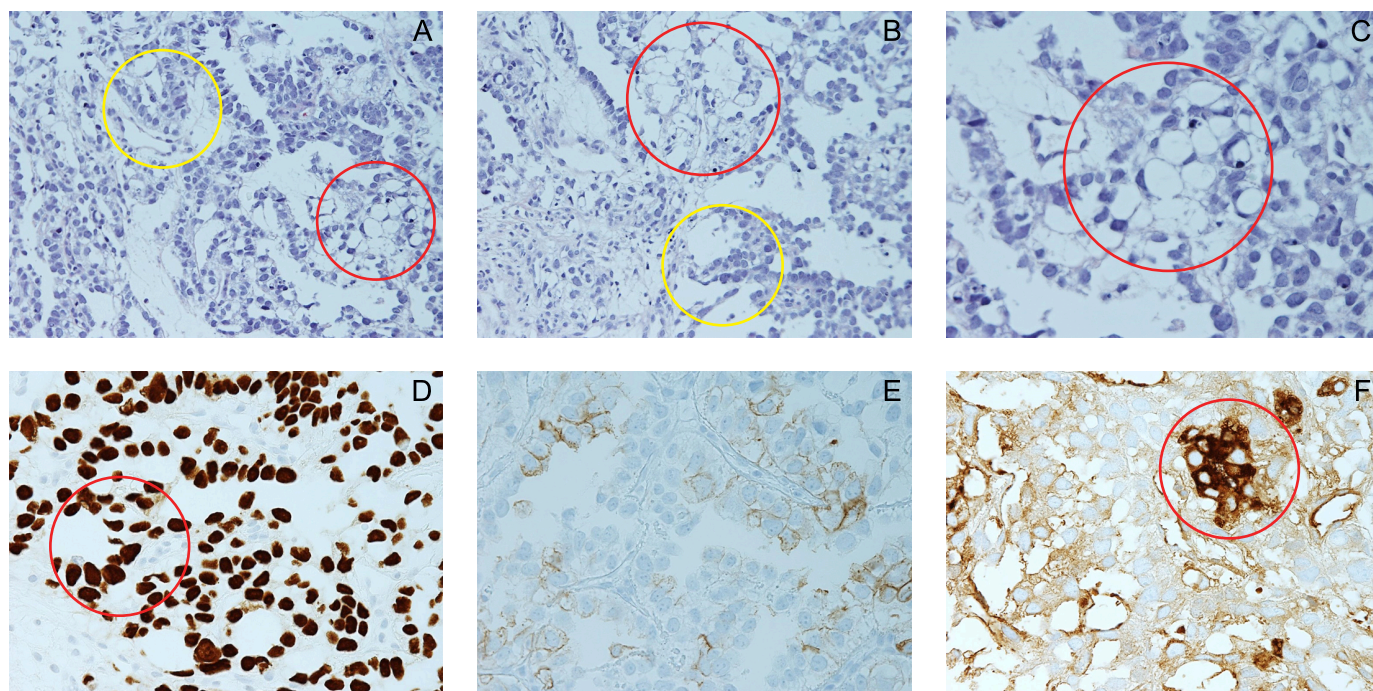


Figure 2 Histopathology of the cervico-uterine mass, which revealed a malignant neoplasm, displaying reticular, cord-like (A and B: yellow ring), and microcystic patterns (A, B, and C: red rings). The tumor is composed of polygonal cells with eosinophilic cytoplasm, round nuclei and occasional prominent nucleoli (hematoxylin-eosin stain, A: x200, B: x200, C: x400). The neoplastic cells demonstrate immunoreactivity for SALL4 with nuclear staining of tumor cells (D: red ring, x400) and for alpha-feto-protein with cytoplasmic staining of tumor cells (F: red ring, x400), consistent with a yolk sac tumor. Immunohistochemical staining with placental alkaline phosphatase shows very weak membranous and cytoplasmic staining of few tumor cells (positive) (E: x400).

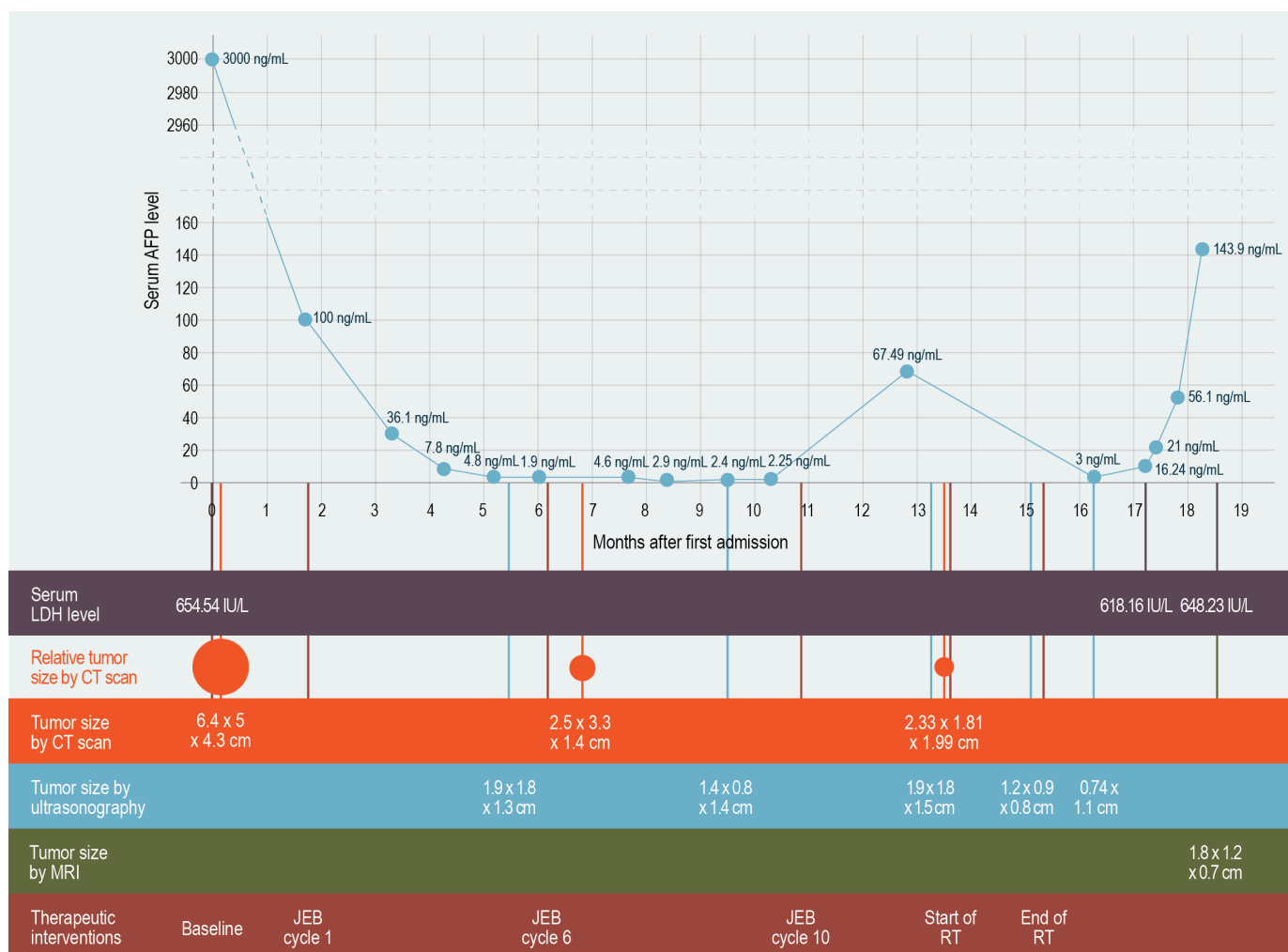


Figure 3 Chart showing temporal relationships of the therapeutic interventions, serum alpha-fetoprotein (AFP) levels, serum lactate dehydrogenase (LDH) levels, and the patient's tumor sizes by computed tomography (CT) scan, ultrasonography, and magnetic resonance imaging (MRI).

to be elevated: >3000 ng/mL (normal 0-9 ng/mL), 736 U/L (normal: 266-500 U/L) and 0.710 mIU/mL (normal: 0.5-1350 mIU/mL), respectively. Computed tomography (CT) of the whole abdomen with oro-rectal contrast (Figure 1) showed a large cervico-uterine mass measuring 6.4 x 5 x 4.3 cm and compressing the sigmoid colon and urinary bladder. At this point, we were considering extragonadal germ cell tumor.

We did a biopsy of the cervico-uterine mass by transvaginal approach. Histopathologic findings revealed areas with reticular, cord-like and microcystic patterns (Figure 2). The neoplastic cells demonstrate immunoreactivity to SALL4, placental alkaline phosphatase (PLAP) and AFP. These findings are consistent with a malignant germ cell tumor, specifically yolk sac tumor (YST). We staged the patient's malignancy (based on the childhood Extragonadal and Extracranial Germ Cell Tumor

staging⁷) as stage III due to the involvement of the regional lymph nodes.

THERAPEUTIC APPROACHES

Our initial goal was to achieve remission by chemotherapy to preserve our patient's reproductive structures. We started the patient on a platinum-based chemotherapy regimen, consisting of six cycles of carboplatin, etoposide and bleomycin (JEB) every 21 days. Serum AFP level monitoring throughout the JEB course showed a gradual decrease from the baseline level of >3,000 ng/mL to its normal range of 9-10 ng/mL. By the sixth cycle, serum AFP level was 1.9 ng/mL (Figure 3).

Repeat CT scan after the JEB course showed a residual mass measuring 2.5 x 3.3 x 1.4 cm (Figure 4), hence we decided to extend the patient's chemotherapy regimen to 4 more cycles. The serum AFP level taken 11 weeks after the end of the tenth cycle was again

elevated at 67.49 ng/ml. A repeat CT scan 3 months after the tenth JEB cycle did not show any significant reduction in the size of the mass (2.33 x 1.81 x 1.99 cm). The patient also started to have hypogastric pain. At this point, we decided to proceed with radiotherapy for local control. The patient underwent 28 fractions of external beam radiation therapy within 50 days. The tumor received a total radiation dose of 5040 cGy. After the radiotherapy, repeat ultrasonography revealed a reduction in the size of the mass to 1.2 x 0.9 x 0.8 cm.

The repeat serum AFP level taken three months after the end of radiotherapy showed further elevation at 143.9 ng/mL (Figure 3). We performed an abdominal magnetic resonance imaging (MRI), which showed the size of the residual mass to be 1.8 x 1.2 x 0.7 cm (Figure 4).

OUTCOMES

Due to the persistence of the mass and the elevated serum AFP levels, we held a multidisciplinary meeting with the Gynecology, Pathology, Radiology, General Surgery, Urology, Pediatric Surgery and Pediatric Oncology services. The consensus was to perform a total hysterectomy with vaginal exploration after obtaining the informed consent of the patient's family. Thorough preparation of the patient for the procedure is underway as of this writing.

DISCUSSION

Bloody vaginal discharge is a common and distressing complaint in the vast majority of women, especially during their reproductive years, but when it occurs in a two-year-old girl whose reproductive tract has not yet fully developed, a variety of conditions must be

considered as possible diagnoses.

Vulvovaginitis is the most common gynecologic problem for prepubertal children presenting with abnormal vaginal discharge, genital pain, pruritus, erythema and dysuria.⁸ This was initially considered in our patient but she did not improve with antibiotic therapy. Other considerations that merit further investigation are trauma, the presence of foreign bodies, or sexual abuse. We ruled out these conditions when the vaginotomy done on the patient showed an intact hymen and did not reveal any foreign body.

Genital tumors are uncommon among children and adolescents, accounting for only 1.5 to 2.0% of all malignancies in this age group.⁹ Vaginal bleeding in the premenarcheal girl is an early symptom and warrants investigation, including vaginotomy.¹⁰ An ultrasonography that was initially done on our patient was able to elucidate the underlying cause of the symptoms and allowed us to perform timely interventions.

Vaginal malignancies are usually embryogenic rhabdomyosarcomas, yolk sac tumors, or vaginal adenocarcinomas.^{9,11} In our patient, the transvaginal biopsy revealed a malignant germ cell tumor. We initially entertained either an embryonal carcinoma or a yolk sac tumor. Immunohistochemical staining, turned positive for SALL4, PLAP and AFP stains, confirming the diagnosis of a yolk sac tumor.¹² It is expected that PLAP staining in YST is often focal, with stain uptake of less than 30% of tumor cells.¹²

Perivascular Schiller-Duval bodies are the most distinctive features of yolk sac tumor,^{12,13} but these structures were not found in the biopsy specimen that we took from our patient. Tumor markers may also help differentiate the germ cell tumors. An elevated serum AFP

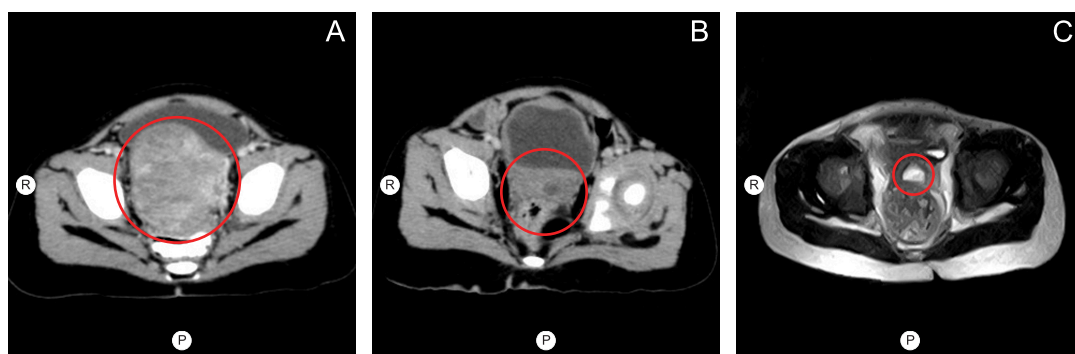


Figure 4 Axial views of abdominal computed tomography (CT) pre-chemotherapy (A), CT post-chemotherapy (B) and magnetic resonance imaging (MRI) 12 weeks post-radiotherapy (C), demonstrating a decrease in the size of the mass in the cervico-uterine region (A, B, and C: red rings). R — right; P — posterior.

level is mostly consistent with yolk sac tumor, while elevated beta-human chorionic gonadotropin (beta-HCG) usually accompanies germinomas or choriocarcinomas.¹⁴

Germ cell tumors, such as YST, mostly occur in the ovaries or testes.⁴ EGGCT, such as YST in the cervix, are extremely rare especially in the pediatric population. This is the first case of YST in the cervix that we have seen in our institution. A review of literature that we did revealed only three reported cases of cervical YST among children less than three years old.⁴⁻⁶ This is the fourth reported case worldwide.

Management of tumors in pediatric gynecology remains challenging since it aims not only to be lifesaving but also to preserve all capabilities for future pregnancy. The management of extragonadal YST may require the prudent combination of surgery, chemotherapy and radiotherapy.

Our patient's pretreatment tumor extended from the cervix to the uterus, displacing the bladder anteriorly and compressing the sigmoid colon. Due to the extent of the tumor, surgical resection would entail total hysterectomy, eliminating any hopes of future childbearing. The decision to originally avoid surgery and to achieve remission by chemotherapy alone was based on our attempt to preserve our patient's sexual and reproductive functions. When chemotherapy alone failed, we pursued radio-therapy, despite the added cost, to achieve local control of the residual tumor.

Chemotherapy with cisplatin, etoposide and bleomycin is the first line of chemotherapy and is the most effective regimen, with a greater than 90% overall survival outcome.¹⁵ In our patient, we used the equally efficacious carboplatin instead of cisplatin in order to avoid the renal toxicity of cisplatin, which commonly occurs among children.¹⁶

Radiotherapy is an acceptable alternative option to surgery for local control following first-line chemotherapy in EGGCT, particularly in the mediastinum.¹⁷ However, its role is less certain among patients with YST in the cervix. In previous case reports on EGGCT, most patients underwent surgical resection with neoadjuvant or adjuvant chemotherapy.⁴⁻⁶ This is the first reported case of YST in the cervix where remission by chemotherapy and local control by radiotherapy were attempted. However, because of the residual tumor and rising serum AFP levels after chemotherapy, we decided to perform surgical removal of

the tumor.

The rarity of malignant extragonadal yolk sac tumors in the cervix compelled us to approach our patient's management with limited information regarding effective treatments or evidence-based management guidelines, and with lack of experience among health care providers. We strongly considered our patient's age, the site of the tumor, and the patient's potential for childbearing when we opted to follow a chemotherapy and radiotherapy course, yet the patient's incomplete response to chemoradiotherapy convinced us to resort to surgery.

Acknowledgments

Our heartfelt gratitude goes to: the Department of Radiological and Imaging Sciences in Southern Philippines Medical Center (SPMC) for providing us the CT and MRI images used in this report; Dr Je-Ann Fabian-Tan of the Department of Radiology in Davao Doctors Hospital for evaluating and providing the labels in the CT and MRI images; Dr Oscar P Grageda and the residents of the Department of Pathology and Laboratories in SPMC for preparing the histopathologic report; and the Division of Clinical Pathology, Department of Pathology in St Jude Children's Research Hospital in Memphis, Tennessee, USA for reviewing the slides and for performing the immunohistostaining.

Patient consent

Obtained through the patient's legally acceptable representative

Reporting guideline used

CARE Checklist
(<http://www.care-statement.org/downloads/CAREchecklist-English.pdf>)

Article source

Submitted

Peer review

External

Competing interests

None declared

Access and license

This is an Open Access article licensed under the Creative Commons Attribution-NonCommercial 4.0 International License, which allows others to share and adapt the work, provided that derivative works bear appropriate citation to this original work and are not used for commercial purposes. To view a copy of this license, visit <http://creativecommons.org/licenses/by-nc/4.0/>

REFERENCES

- Herzog CE, Huz WW. Gonadal and germ cell neoplasms. In: Kleigman R, Stanton B, St. Geme J, Schor N, editors. *Nelson Textbook of Pediatrics*. 19th ed. Pasadena: Elsevier; c2015.
- Mahzouni P, Pejhan SA, Mahmoud. Yolk Sac Tumor of Vagina. *Medical Journal of The Islamic Republic of Iran*. 2016;20(3):155-7.
- Schmoll HJ. Extragonadal germ cell tumors. *Ann Oncol*. 2002;13 Suppl 3:265-272.
- Chen SJ, Li YW, Tsai WY. Endodermal sinus (yolk sac) tumor of vagina and cervix in an infant. *Pediatric Radiology*. 1993;23(1):57-8.

5. Yadav K, Singh G, Budhiraja S, Radhika S. Endodermal sinus tumour of cervix—case report. *Indian J Cancer*. 1996 Mar;33(1):43-5.
6. Gangopadhyay M, Raha K, Sinha SK, De A, Bera P, Pati S. Endodermal sinus tumor of the vagina in children: A report of two cases. *Indian J Pathol Microbiol*. 2009 Jul-Sep;52(3):403-4.
7. Children's Cancer Research Fund [Internet]. Researchers look for a genetic source of childhood tumors. Germ Cell Tumors. Available from: http://www.childrenscancer.org/main/germ_cell_tumors.
8. Koumantakis EE, Hassan EA, Deligeorgiou EK, Creatsas GK. Vulvovaginitis during childhood and adolescence. *Journal of Pediatric and Adolescent Gynecology*. 1997 Feb;10(1):39-43.
9. Horejsí J, Rob L. [Malignant tumors of the female genitalia in childhood—yesterday, today and tomorrow]. *Cas Lek Cesk*. 2003 Feb;142(2):84-7.
10. Imai A, Furui T, Tamaya T. Gynecologic tumors and symptoms in childhood and adolescence; 10-years' experience. *Int J Gynaecol Obstet*. 1994 Jun;45(3):227-34.
11. Fernandez-Pineda I, Spunt SL, Parida L, Krasin MJ, Davidoff AM, Rao BN. Vaginal tumors in childhood: the experience of St. Jude Children's Research Hospital. *J Pediatr Surg*. 2011;46(11):2071-2075.
12. Wang F, Liu A, Peng Y, Rakheja D, Wei L, Xue D, et al. Diagnostic utility of SALL4 in extragonadal yolk sac tumors: an immunohistochemical study of 59 cases with comparison to placental-like alkaline phosphatase, alpha-fetoprotein, and glypican-3. *Am J Surg Pathol*. 2009 Oct;33(10):1529-39.
13. Rosai J. Rosai and Ackerman's Surgical Pathology. 10th ed. Mosby; 2011. 1350 p.
14. Motawy MS, Szymendera JJ, al-Jazzaf H, Behbehani AE, Foudeh MO, Ebraheem AK, et al. Serum AFP, hCG and CEA in the management of patients with testicular, ovarian and extragonadal germ cell tumors. *Int J Biol Markers*. 1992 Apr-Jun;7(2):80-6.
15. International germ cell consensus classification; a prognostic factor based staging system for metastatic germ cell cancers. *J Clin Oncol*. 1997 Feb;15(2):594-603.
16. Mann JR, Raafat F, Robinson K, Imeson J, Gornall P, Sokal M, et al. The United Kingdom Children's Cancer Study Group's second germ cell tumor study: carboplatin, etoposide, and bleomycin are effective treatment for children with malignant extracranial germ cell tumors, with acceptable toxicity. *J Clin Oncol*. 2000 Nov 15;18(22):3809-18.
17. Wang J, Bi N, Wang X, Hui Z, Liang J, Lv J, et al. Role of radiotherapy in treating patients with primary malignant mediastinal non-seminomatous germ cell tumor: A 21-year experience at a single institution. *Thorac Cancer*. 2015 Jul;6(4):399-406.

Editorial Team Southern Philippines Medical Center Journal of Health Care Services

Editor-in-chief: Alvin S. Concha • **Issue Editors:** Aura Rhea D. Lanaban, Eugene Lee L. Barinaga

Associate Editors: Seurinane Sean B. Española, Joseph Jasper S. Acosta • **Layout Editors:** Jaryll Gerard L. Ampog, Rodel C. Roño, Clarence Xlasi D. Ladrero

Managing Editor: Clarence Xlasi D. Ladrero

SPMC JHCS OFFICE Hospital Research Office, Level 1 Outpatient Building, Southern Philippines Medical Center, JP Laurel Avenue, Davao City, Philippines
Landline (+6382) 2272731 loc 4615 • **Website** <http://spmcpapers.com> • **Email** info@spmcpapers.com